



## Current dipole orientation and distribution of epileptiform activity correlates with cortical thinning in left mesiotemporal epilepsy

Claus Reinsberger<sup>a,b,c</sup>, Naoaki Tanaka<sup>a</sup>, Andrew J. Cole<sup>d</sup>, Jong Woo Lee<sup>c</sup>, Barbara A. Dworetzky<sup>c</sup>, Edward B. Bromfield<sup>c,1</sup>, Lorie Hamiwka<sup>e</sup>, Blaise F. Bourgeois<sup>f</sup>, Alexandra J. Golby<sup>g</sup>, Joseph R. Madsen<sup>h</sup>, Steven M. Stuffelbeam<sup>c,i,\*</sup>

<sup>a</sup> Department of Radiology, Athinoula A. Martinos Center for Biomedical Imaging, Massachusetts General Hospital, 149 Thirteenth Street, Charlestown, MA 02129, USA

<sup>b</sup> Department of Neurology, Ludwig Maximilians University, Josef-Schneider-Str. 11, 97078 Wuerzburg, Germany

<sup>c</sup> Department of Neurology, Brigham and Women's Hospital, 75 Francis St., Boston, MA 02115, USA

<sup>d</sup> Epilepsy Service, Massachusetts General Hospital, 55 Fruit Street, Boston, MA 02114, USA

<sup>e</sup> Division of Child Neurology, Ohio State University College of Medicine, Columbus, OH 43210, USA

<sup>f</sup> Department of Neurology, Children's Hospital Boston, 300 Longwood Avenue, Boston, MA 02115, USA

<sup>g</sup> Department of Neurosurgery and Radiology, Brigham and Women's Hospital, 75 Francis St., Boston, MA 02115, USA

<sup>h</sup> Department of Neurosurgery, Children's Hospital Boston, 300 Longwood Avenue, Boston, MA 02115, USA

<sup>i</sup> Division of Health Sciences and Technology, Harvard Massachusetts Institute of Technology, 77 Massachusetts Avenue, Cambridge, MA 02139, USA

### ARTICLE INFO

#### Article history:

Received 11 January 2010

Revised 16 April 2010

Accepted 28 April 2010

Available online 21 May 2010

### ABSTRACT

To evaluate cortical architecture in mesial temporal lobe epilepsy (MTLE) with respect to electrophysiology, we analyze both magnetic resonance imaging (MRI) and magnetoencephalography (MEG) in 19 patients with left MTLE. We divide the patients into two groups: 9 patients (Group A) have vertically oriented antero-medial equivalent current dipoles (ECDs). 10 patients (Group B) have ECDs that are diversely oriented and widely distributed. Group analysis of MRI data shows widespread cortical thinning in Group B compared with Group A, in the left hemisphere involving the cingulate, supramarginal, occipitotemporal and parahippocampal gyri, precuneus and parietal lobule, and in the right hemisphere involving the fronto-medial, -central and -basal gyri and the precuneus. These results suggest that regardless of the presence of hippocampal sclerosis, in a subgroup of patients with MTLE a large cortical network is affected. This finding may, in part, explain the unfavorable outcome in some MTLE patients after epilepsy surgery.

© 2010 Elsevier Inc. All rights reserved.

### Introduction

Mesial temporal lobe epilepsy (MTLE) is the most common form of surgically treated epilepsy. However, despite extensive presurgical evaluations at tertiary epilepsy centers, there is still a high rate of surgical failures, typically 20–30% as measured by the recurrence of seizures within one year (Spencer and Huh, 2008). Surgical failure has many potential causes, such as propagation of epileptic spikes from the mesial temporal structures to the neocortex, which is subsequently damaged and becomes epileptogenic (Spencer and Huh, 2008). The presence of hippocampal sclerosis (HS) is recognized as a good prognostic factor and MTLE patients with HS sometimes undergo resective surgery without further evaluation by using intracranial electroencephalography (EEG) or magnetoencephalography

(MEG). However, patients with HS also may fail surgery (Spencer and Huh, 2008) and the cause of this failure is still unclear.

Classical theories of MTLE pathogenesis have focused mainly on abnormalities and damage restricted to mesiotemporal structures (Bernasconi et al., 2004; Duzel et al., 2006; Jack, 1994). More recent studies using volumetric magnetic resonance imaging (MRI) analysis have demonstrated that MTLE patients have widespread cortical thinning involving temporal and extratemporal structures including cingulum, thalamus, and frontal and parietal lobes (Mueller et al., 2006; Seidenberg et al., 2005). These studies support a revised hypothesis implicating widespread cortical involvement in the pathophysiology of MTLE.

The clinical relevance of the widespread cortical involvement remains unclear. A significant difference in cortical thinning has been demonstrated in left TLE as compared to right TLE (Bonilha et al., 2007). Other studies of TLE have revealed that both patients with and without HS have widespread cortical thinning extending beyond the temporal lobe (Mueller et al., 2006). It is unclear whether this widespread pattern of cortical atrophy is related to subsequent surgical failure, possibly indicating either multifocal foci or a widespread

\* Corresponding author. Athinoula A. Martinos Center for Biomedical Imaging, Massachusetts General Hospital, 149 Thirteenth Street, Charlestown, MA 02129, USA. Fax: +1 617 726 7422.

E-mail address: [sms@nmr.mgh.harvard.edu](mailto:sms@nmr.mgh.harvard.edu) (S.M. Stuffelbeam).

<sup>1</sup> Deceased.

secondary process. One approach is to explore the meaning of these structural changes may be to examine their relationship to interictal epileptiform discharges.

Dipole source localization of electromagnetic epileptic activities has previously suggested distant cortical involvement in MTLE (Ebersole et al., 2008). In one classification there are two types of spikes in patients with temporal lobe epilepsy, according to their dipolar current distribution and orientation: “Type 1” dipoles with vertical orientation correspond to inferior or basal temporal spikes and “Type 2” dipoles with horizontal orientation correspond to lateral temporal spikes (Ebersole et al., 2008). The relationship between spike distribution and morphological changes of the cortex is still unclear, although spikes with Type 2 dipoles may portend a less favorable surgical outcome (Ebersole et al., 2008).

In the present study, we evaluate whole-brain cortical thickness with surface-based methods and compare the cortical thickness between two groups of MTLE patients according to the spike sources of their epileptic discharges. Our goal is to determine differences in the cortical thickness and affected cortical networks based on the spatial distribution of epileptic discharges in patients with TLE.

## Patients and methods

### Patients

We reviewed all patients with epilepsy referred to the clinical MEG service as part of their routine presurgical evaluation. The diagnosis of TLE was based on ictal non-invasive electroencephalography prior to referral to the MEG service. Patients with non-temporal lobe epilepsy, apparent lesions on clinical MRI scans other than HS, or with previous surgical procedures were eliminated. Patients with right TLE were to be analyzed separately, as their pattern of cortical atrophy has been described as being distinct from left TLE (Ahmadi et al., 2009; Bonilha et al., 2007). Only seven patients were identified, so further analysis for this study was not possible. Of the patients with left TLE, only patients with MTLE as determined by clinical seizure semiology were selected. This was based on the ictal semiology as described in the literature and by the ILAE classification (Engel, 2001; Loddenkemper and Kotagal, 2005), consisting of ipsilateral typical mesial temporal lobe automatisms alone or in combination with contralateral dystonic posturing or epigastric auras. Patients with other ictal signs, especially with auditory auras or déjà-vu auras, alone or in combination with the above mentioned semiological signs were excluded, as they may represent neocortical, lateral temporal lobe seizures (Loddenkemper and Kotagal, 2005). All patients consented according to the Institutional Human Research Subject guidelines.

### Data acquisition

MR images were acquired on a 3 T scanner (Trio, Siemens Ltd., Erlangen, Germany) with sequences optimized for maximum gray-white matter contrast (12-channel head coil, sagittal 3-D T1-weighted MPRAGE volumes, FOV 24 cm, isometric 1 mm voxels). MEG was acquired by using a 306-channel VectorView (Elekta-Neuromag Oy, Helsinki, Finland) in a magnetically shielded room. Simultaneous 70-electrode EEG was recorded using a MEG-compatible cap (Elekta-Neuromag Oy, Helsinki, Finland). Recordings were visually examined, and temporal epileptic spikes on EEG or MEG were used for subsequent MEG analysis. Equivalent current dipoles (ECDs) were calculated at the peak of each spike according to a single dipole model. ECDs were selected, if a value of goodness of fit was greater than 70% and the current dipole moment was less than 500 nAm (nano-ampere \* meters). These ECDs were projected onto the patient's own MRI.

Patients were divided into two groups according to the MEG results. Group A consisted of the patients who had ECDs in the

anterior and medial temporal lobe with vertical orientation. Two patients had no definite spikes or no adequate ECDs during the recording sessions. They were also classified in this group as they had previous left anterior temporal sharp waves and left temporal seizure onset on previous EEG recordings. Further, elimination of these patients did not significantly change the results of the study. Group B included the patients who had ECDs in the posterior and lateral temporal lobe, often in widespread areas irrespective of the current dipole orientations.

### Image analysis

MR images were used for cortical analysis by a semi-automated technique (Freesurfer-FSL software, version 4.0) (Dale et al., 1999). Smoothing was performed on a surface tessellation using an iterative nearest neighbor average, which is equivalent to a full-width half-maximum of approximately 6 cm. After cortical parcellation and reconstruction, a general linear model (GLM) was used for a group analysis of cortical surface as the main effect (Fischl et al., 1999a), where the two groups were based on the MEG findings (see above). Correlations were corrected for potential confounds of age and the duration of epilepsy for each patient. This was performed by removing these confounders in the correlation, i.e. using age and duration of epilepsy as ‘nuisance regressors’ (Fischl et al., 1999a). Statistical thickness difference maps with a significance threshold of  $p < 0.05$  were constructed using a  $t$  statistic and displayed on an inflated cortex (Fig. 2).

## Results

A total of 180 patients with epilepsy were retrospectively reviewed. 64 patients had temporal lobe epilepsy. We identified 19 patients with clear left mesial temporal lobe seizures (Table 1). MEG results of these patients revealed nine patients in Group A and 10 patients in Group B (Fig. 1). Three patients showed hippocampal signal and/or volume change on standard MRI scans (two patients in

**Table 1**  
Clinical summary.

	Age [years]	Gender	Seizure onset [years of life]	Duration of epilepsy [years]
Group A	36	Female	31	5
	18	Female	10	8
	37 <sup>a</sup>	Male	8	29
	51	Female	35	16
	30	Female	25	5
	35	Female	19	16
	44 <sup>b</sup>	Female	40	4
	32 <sup>b</sup>	Male	14	18
	50 <sup>a</sup>	Male	45	5
Mean/SD	37/9.74		25.25/13.38	12.63/8.15
Group B	21	Male	15	6
	16	Male	9	7
	48	Female	19	29
	52	Female	25	27
	16	Female	1	15
	49	Female	29	20
	26	Male	21	5
	50	Male	26	24
	29	Male	22	7
	43 <sup>b</sup>	Male	10	33
Mean/SD	35/14.06		17.5/9.20	20.00/9.58

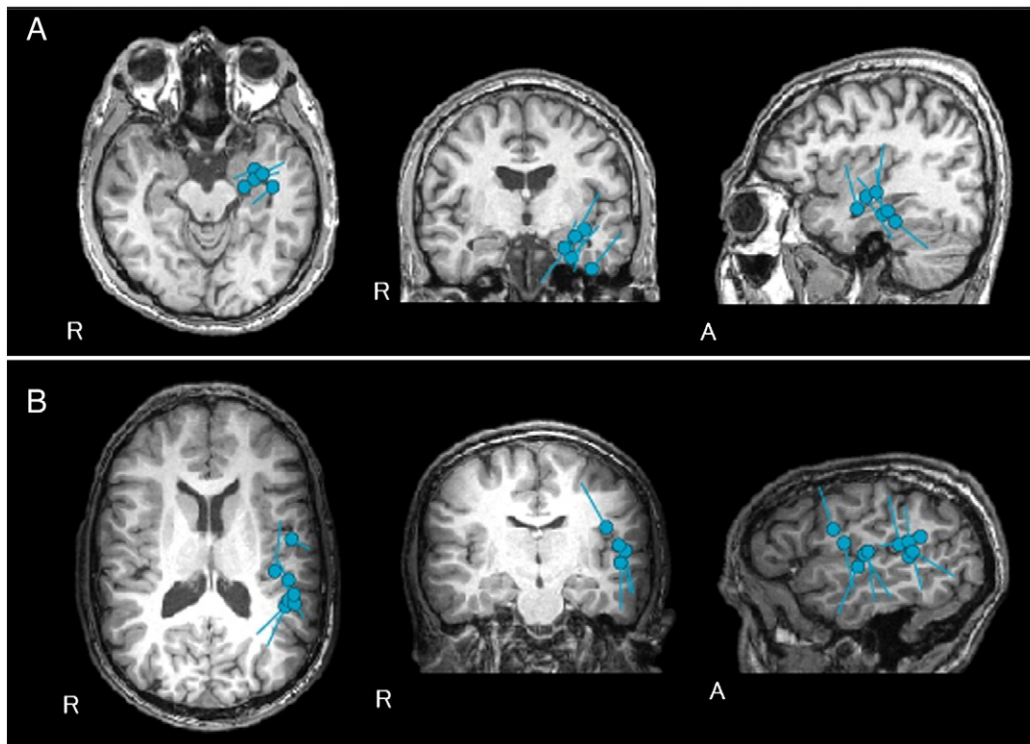
Group A: antero-medial source distribution of MEG spikes with vertical orientation, or no definite spikes or no adequate current dipoles.

Group B: posterior-lateral/widespread source distribution of MEG spikes with various orientations.

SD: standard deviation.

<sup>a</sup> No spikes on MEG.

<sup>b</sup> HS on MRI.



**Fig. 1.** Typical patterns of ECD distribution and orientation in Groups A and B. A. Group A: ECDs are distributed in the anterior medial temporal lobe with vertical orientation. B. Group B: ECDs are distributed in the lateral temporal and frontal lobes with variable orientation. Note that in Group A the dipole orientation is consistent across the ECD locations, whereas Group B has variable dipole orientations.

Group A, 1 patient in Group B). MRI scans of the other patients in Groups A and B were non-lesional as determined by an experienced radiologist (SMS).

Group comparison of the left hemisphere revealed significant cortical thinning most prominent in the cingulate gyrus, supramarginal gyrus, precuneus, parietal lobule, occipitotemporal and parahippocampal gyrus in Group B as compared with Group A (Fig. 2). Significantly thinned cortex was also seen in the fronto-medial, -central and -basal gyri and the precuneus of the right hemisphere. The mean cortical thicknesses of each patient at two representative areas of cortical thinning were calculated (Fig. 2).

## Discussion

In this study, we evaluated cortical thinning using surface-based analysis in two groups of MTL patients defined by the distribution and orientation of their interictal spike ECDs. This is the first study that investigates cortical thinning in relation to electrophysiological parameters in patients with epilepsy. We found that there is significant cortical thinning in patients with posterior-lateral/widespread source distribution as compared to patients with antero-medial source distribution.

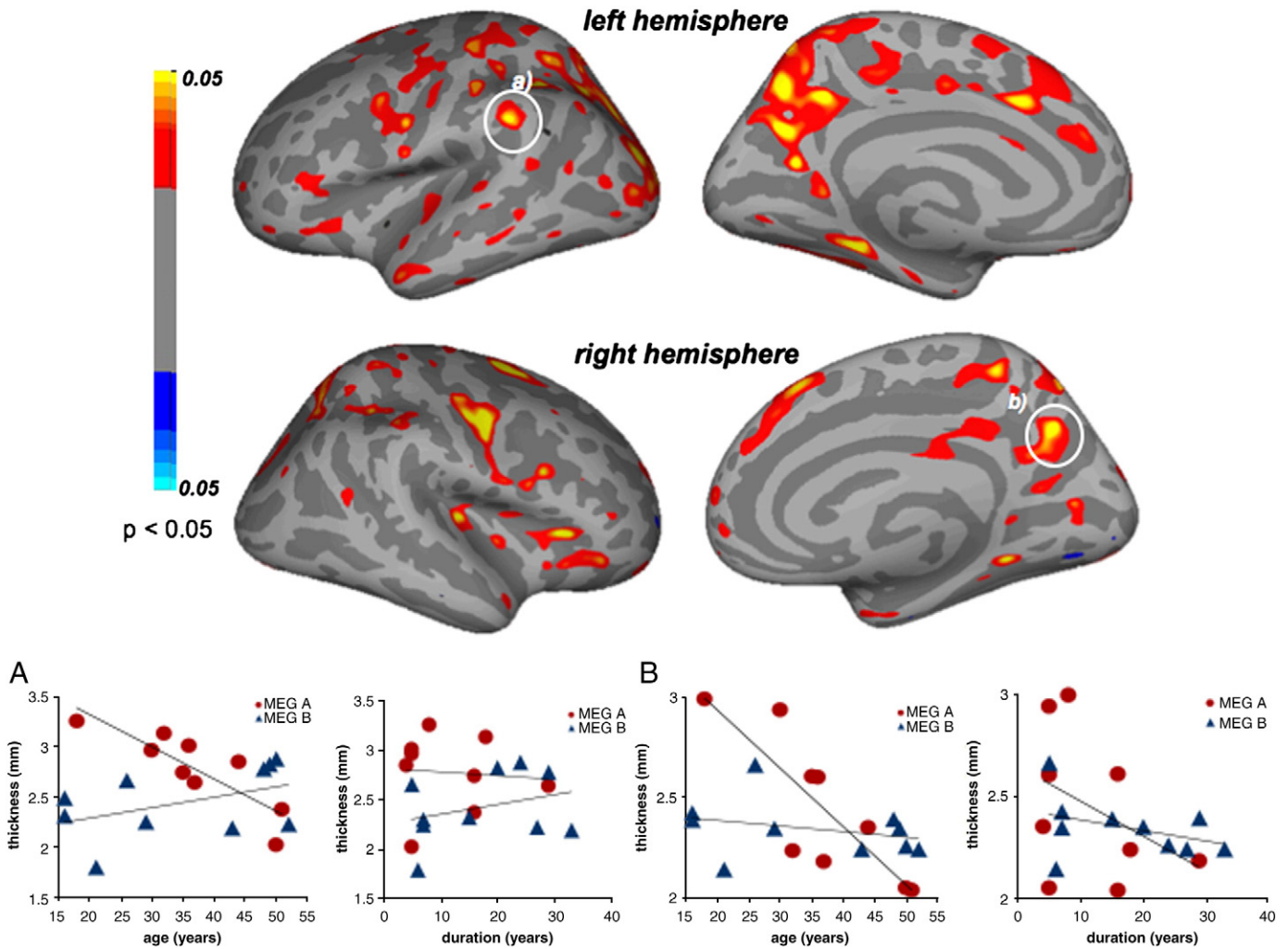
There were two types of dipole distributions in our study: localized and distributed. This distinction is a modification of the classification proposed by Ebersole (Ebersole, 1991; Ebersole et al., 2008). Patients with frequent spikes and a varied dipole orientation demonstrate a widespread pattern of cortical thinning that goes beyond the temporal lobe, with pronounced atrophy of structures of the limbic system as well as frontal, and parietal lobe. These results are consistent with previous studies that showed that patients with antero-medial dipole localization have limited propagation of epileptic discharges and therefore have good surgical outcomes, whereas patients with widespread dipole distribution have widespread cortical involvement of pathophysiology and may have an unfavorable surgical outcome (Iwasaki et al., 2002). Based on these findings,

grouping patients based on source dipole distribution and orientation demonstrates important differences in the pathophysiology of MTL. Temporal lobectomies in these patients may potentially result in a poorer surgical outcome since they have more distant cortical involvement, even though the clinical manifestation of patients in both groups is similar. Future studies with larger numbers of patients and examination of postsurgical clinical information are needed to test this hypothesis, as not all patients of our study subsequently underwent surgery. Furthermore, a spatial correlation between scattered ECDs and the multifocal cortical thinning in group B was not performed due to the relatively low number of patients.

Our study extends the results of previous studies that suggested MTL affects not only mesiotemporal structures but also a more distant cortical network (Duzel et al., 2006; McDonald et al., 2008; Mueller et al., 2009). One possible explanation for distant cortical abnormality is the existence of dual pathology that includes both an extrahippocampal structural lesion as well as hippocampal sclerosis. Due to the strict selection according to seizure semiology and the absence of neocortical structural abnormalities in the MRI scans, additional lateral lesions appear unlikely in our patients. Possible dual pathologies are furthermore believed to be of little importance in MTL (Spencer and Huh, 2008). An alternative possibility is that distant cortical thinning is a secondary effect of recurrent seizures or status epilepticus, which was accounted for by using duration of epilepsy and age as a nuisance regressor in the current analysis. Based on the regression, duration of epilepsy does have an effect on cortical thinning, but the cortical thinning effect remains significant for the comparison of both groups when the effect of duration and age of the patients is accounted for.

We have utilized cortical surface-based analysis in this study rather than voxel based morphometry (VBM). Cortical parcellation and reconstruction can be performed accurately and nearly automatically (Dale et al., 1999). Cortical surface-based analysis is objectively performed by using this technique, and the use of a spherical coordinate transformation offers more accurate gyral alignments





**Fig. 2.** (Top) Statistical cortical thickness difference maps from the comparison of Groups A and B. Yellow and red colors indicate thicker cortices in Group A, and blue and turquoise colors indicate thicker cortices in Group B. All colored areas have the statistical difference of  $p < 0.05$  (corrected for age and duration of epilepsy). Mean cortical thickness of each patient, obtained from the circled subregions of a) and b) is shown at the bottom of the figure, plotted versus age and duration of epilepsy.

across subjects than volumetric measurements, which improves the ability to compare cortical thicknesses across groups (Fischl et al., 1999b). Mueller et al. (2009, 2006) compared two groups of MTLE patients divided by the presence or absence of HS and found no significant difference in their cortical thickness using VBM (Mueller et al., 2006), whereas surface-based analysis demonstrated a different pattern of cortical thinning in MTLE with HS in comparison to MTLE without HS (Mueller et al., 2009). However, it was not differentiated for the affected side or the duration of epilepsy.

This study could address left TLE patients exclusively, due to low numbers of right TLE. The cortical thinning pattern in right TLE, however, has been shown to be distinct from right TLE patients (Ahmadi et al., 2009; Bonilha et al., 2007), which suggests that the correlation of epileptic discharges might also be different. We plan to include more right TLE patients in a future study to determine if a similar correlation of epileptic discharges and the cortical thinning exists.

In our study only three out of 19 patients had HS on MRI. This most probably reflects a selection bias in patients with MTLE referred to the MEG service prior to possible surgery. We note that MTLE patients with HS often have surgery without any further evaluation such as MEG. Since this is a retrospective study, the lack of patient with HS is a potential source of bias in our patient selection criteria. However, patients with HS also may fail surgery (Spencer and Huh, 2008), and

the causes of this failure is still unclear. We hope to include patients with HS in a future study to determine whether source analysis might also be helpful in these patients.

So far, the presence of HS is becoming recognized as a prognostic factor concerning favorable outcome after surgery (Spencer and Huh, 2008). Our study suggests that an electrophysiological marker may be useful in the absence of gross structural lesions such as HS in predicting the anatomic extent of involvement in patients, who have clinical manifestations of MTLE. However, the presence of HS in both MEG-groups supports that the presence of HS alone may not be a solely useful parameter to subdivide MTLE patients with respect to surgical outcome, although larger numbers of patients with and without HS are needed to support this hypothesis. Neurophysiologic source analysis complements structural imaging and may have implications for the selection of patients, extent of procedures, and prediction of prognosis in patients with TLE. In conjunction with intracranial EEG recordings, the described analysis may provide additional information leading to a more informed decision regarding the likely success of resective surgery.

**Conclusion**

Our results suggest that a subgroup of MTLE patients with a widespread source distribution of epileptic spikes has a more

widespread cortical thinning beyond the mesiotemporal region. Future correlation of the presented combined approach of source analysis of epileptic spikes and surface-based cortical morphometry with clinical outcome after surgery may provide corroborating and potentially possibly prognostic information for patients undergoing surgical evaluation for MTLE.

### Acknowledgments

This work was supported by an educational grant of the Felgenhauer Stiftung of the German Neurological Society, National Institutes of Health (P41RR14075, RO1NS037462-07, 5K08MH067966, U41-RR019703, and P01CA067165), Mental Illness and Neuroscience Discovery Institute, NARSAD Young Investigators Award, Japan Epilepsy Research Foundation, Brain Science Foundation, and Klarman Family Foundation.

### References

- Ahmadi, M.E., Hagler Jr., D.J., McDonald, C.R., Tecoma, E.S., Iragui, V.J., Dale, A.M., Halgren, E., 2009. Side matters: diffusion tensor imaging tractography in left and right temporal lobe epilepsy. *AJNR Am. J. Neuroradiol.* 30, 1740–1747.
- Bernasconi, N., Duchesne, S., Janke, A., Lerch, J., Collins, D.L., Bernasconi, A., 2004. Whole-brain voxel-based statistical analysis of gray matter and white matter in temporal lobe epilepsy. *NeuroImage* 23, 717–723.
- Bonilha, L., Rorden, C., Halford, J.J., Eckert, M., Appenzeller, S., Cendes, F., Li, L.M., 2007. Asymmetrical extra-hippocampal grey matter loss related to hippocampal atrophy in patients with medial temporal lobe epilepsy. *J. Neurol. Neurosurg. Psychiatry* 78, 286–294.
- Dale, A.M., Fischl, B., Sereno, M.I., 1999. Cortical surface-based analysis. I. Segmentation and surface reconstruction. *NeuroImage* 9, 179–194.
- Duzel, E., Schiltz, K., Solbach, T., Peschel, T., Baldeweg, T., Kaufmann, J., Szentkuti, A., Heinze, H.J., 2006. Hippocampal atrophy in temporal lobe epilepsy is correlated with limbic systems atrophy. *J. Neurol.* 253, 294–300.
- Ebersole, J.S., 1991. EEG dipole modeling in complex partial epilepsy. *Brain Topogr.* 4, 113–123.
- Ebersole, J.S., Stefan, H., Baumgartner, C., 2008. Electroencephalographic and magnetoencephalographic source modeling. In: Engel, J., Pedley, T. (Eds.), *Comprehensive Epileptology*. Lippincott-Raven, Philadelphia, pp. 895–915.
- Engel Jr., J., 2001. A proposed diagnostic scheme for people with epileptic seizures and with epilepsy: report of the ILAE Task Force on Classification and Terminology. *Epilepsia* 42, 796–803.
- Fischl, B., Sereno, M.I., Dale, A.M., 1999a. Cortical surface-based analysis. II: Inflation, flattening, and a surface-based coordinate system. *NeuroImage* 9, 195–207.
- Fischl, B., Sereno, M.I., Tootell, R.B., Dale, A.M., 1999b. High-resolution intersubject averaging and a coordinate system for the cortical surface. *Hum. Brain Mapp.* 8, 272–284.
- Iwasaki, M., Nakasato, N., Shamoto, H., Nagamatsu, K., Kanno, A., Hatanaka, K., Yoshimoto, T., 2002. Surgical implications of neuromagnetic spike localization in temporal lobe epilepsy. *Epilepsia* 43, 415–424.
- Jack Jr., C.R., 1994. MRI-based hippocampal volume measurements in epilepsy. *Epilepsia* 35 (Suppl 6), S21–S29.
- Loddenkemper, T., Kotagal, P., 2005. Lateralizing signs during seizures in focal epilepsy. *Epilepsy Behav.* 7, 1–17.
- McDonald, C.R., Hagler Jr., D.J., Ahmadi, M.E., Tecoma, E., Iragui, V., Gharapetian, L., Dale, A.M., Halgren, E., 2008. Regional neocortical thinning in mesial temporal lobe epilepsy. *Epilepsia* 49 (5), 794–803.
- Mueller, S.G., Laxer, K.D., Cashdollar, N., Buckley, S., Paul, C., Weiner, M.W., 2006. Voxel-based optimized morphometry (VBM) of gray and white matter in temporal lobe epilepsy (TLE) with and without mesial temporal sclerosis. *Epilepsia* 47, 900–907.
- Mueller, S.G., Laxer, K.D., Barakos, J., Cheong, I., Garcia, P., Weiner, M.W., 2009. Widespread neocortical abnormalities in temporal lobe epilepsy with and without mesial sclerosis. *NeuroImage* 46, 353–359.
- Seidenberg, M., Kelly, K.G., Parrish, J., Geary, E., Dow, C., Rutecki, P., Hermann, B., 2005. Ipsilateral and contralateral MRI volumetric abnormalities in chronic unilateral temporal lobe epilepsy and their clinical correlates. *Epilepsia* 46, 420–430.
- Spencer, S., Huh, L., 2008. Outcomes of epilepsy surgery in adults and children. *Lancet Neurol.* 7, 525–537.