

# Neurology®

## **The Landau–Kleffner syndrome of acquired epileptic aphasia: Unusual clinical outcome, surgical experience, and absence of encephalitis**

A. J. Cole, F. Andermann, L. Taylor, et al.

*Neurology* 1988;38:31

DOI 10.1212/WNL.38.1.31

**This information is current as of January 1, 1988**

The online version of this article, along with updated information and services, is located on the World Wide Web at:

<http://www.neurology.org/content/38/1/31.full.html>

*Neurology*® is the official journal of the American Academy of Neurology. Published continuously since 1951, it is now a weekly with 48 issues per year. Copyright © 1988 by the American Academy of Neurology. All rights reserved. Print ISSN: 0028-3878. Online ISSN: 1526-632X.



# The Landau-Kleffner syndrome of acquired epileptic aphasia: Unusual clinical outcome, surgical experience, and absence of encephalitis

A.J. Cole, MD, FRCP(C); F. Andermann, MD, FRCP(C); L. Taylor, MA; A. Olivier, MD, PhD, FRCS(C); T. Rasmussen, MD, FRCS(C); Y. Robitaille, MD, FRCP(C); and J-P. Spire, MD

**Article abstract**—The syndrome of acquired verbal auditory agnosia in childhood with mutism and epileptic discharges has been described in over 100 cases. An encephalitic etiology has often been postulated but never proved. We report two patients with this syndrome who were treated surgically. Despite careful search, no pathologic evidence of encephalitis was found. One patient, with the typical course, had no seizures but striking positive correlation between epileptic discharge and language disorder; the second, after classic onset, developed intractable temporal lobe epilepsy, a previously unreported outcome of this syndrome. EEG discharges are generalized, bilateral, multifocal, or with shifting predominance but mainly temporal in 85% of reported cases, and unilateral, also predominantly temporal, in 15%. Language areas are preferentially involved. This syndrome has certain biologic features that resemble the benign epilepsies of childhood and may be the result of the unusual localization of the epileptic abnormality.

NEUROLOGY 1988;38:31-38

In 1957, Landau and Kleffner described six children with a syndrome of "acquired aphasia with convulsive disorder."<sup>1</sup> Since then, over 100 additional cases have been reported.<sup>1-33</sup> The disorder is characterized by the acute or subacute appearance of language difficulty in previously normal children. Convulsions, if they occur, may precede or follow the onset of language dysfunction, but electrographic epileptic discharges are invariably present. Prognosis is variable, but improvement of electrographic abnormalities seems weakly correlated with resolution of language difficulty. Although persistent or intractable epilepsy is exceptional, long-lasting language deficits have been described.

The nature of the language abnormality has been best characterized by Rapin et al.<sup>23</sup> Unlike typical acquired childhood aphasia,<sup>34</sup> receptive dysfunction seems to dominate the clinical picture early in this disorder, so that affected children are often considered to have lost their hearing. Expressive deficits may develop later. Reading and writing, as well as the use of sign language, may be relatively spared, suggesting that the children have a verbal auditory agnosia associated with varying degrees of mutism, and not true aphasia. The majority of reported cases demonstrate acquired language dysfunction, but a number of children with "developmental aphasia" have been considered by some authors to fit into the spectrum of the Landau-Kleffner

syndrome, insofar as no structural lesions are demonstrated and epileptic EEG abnormalities with or without clinical seizures are present.<sup>2,18,23,27</sup> The etiology of this disorder remains unclear but an encephalitic process has often been postulated.<sup>10,15,16,20</sup> We present two patients with convulsive disorder and verbal auditory agnosia and mutism (VAAM) treated with anterior temporal lobectomy because medical therapy failed to alleviate the language deficit in one, and to control the seizures in the second. In both cases, neuropathologic studies revealed mild gliosis but no evidence of encephalitis.

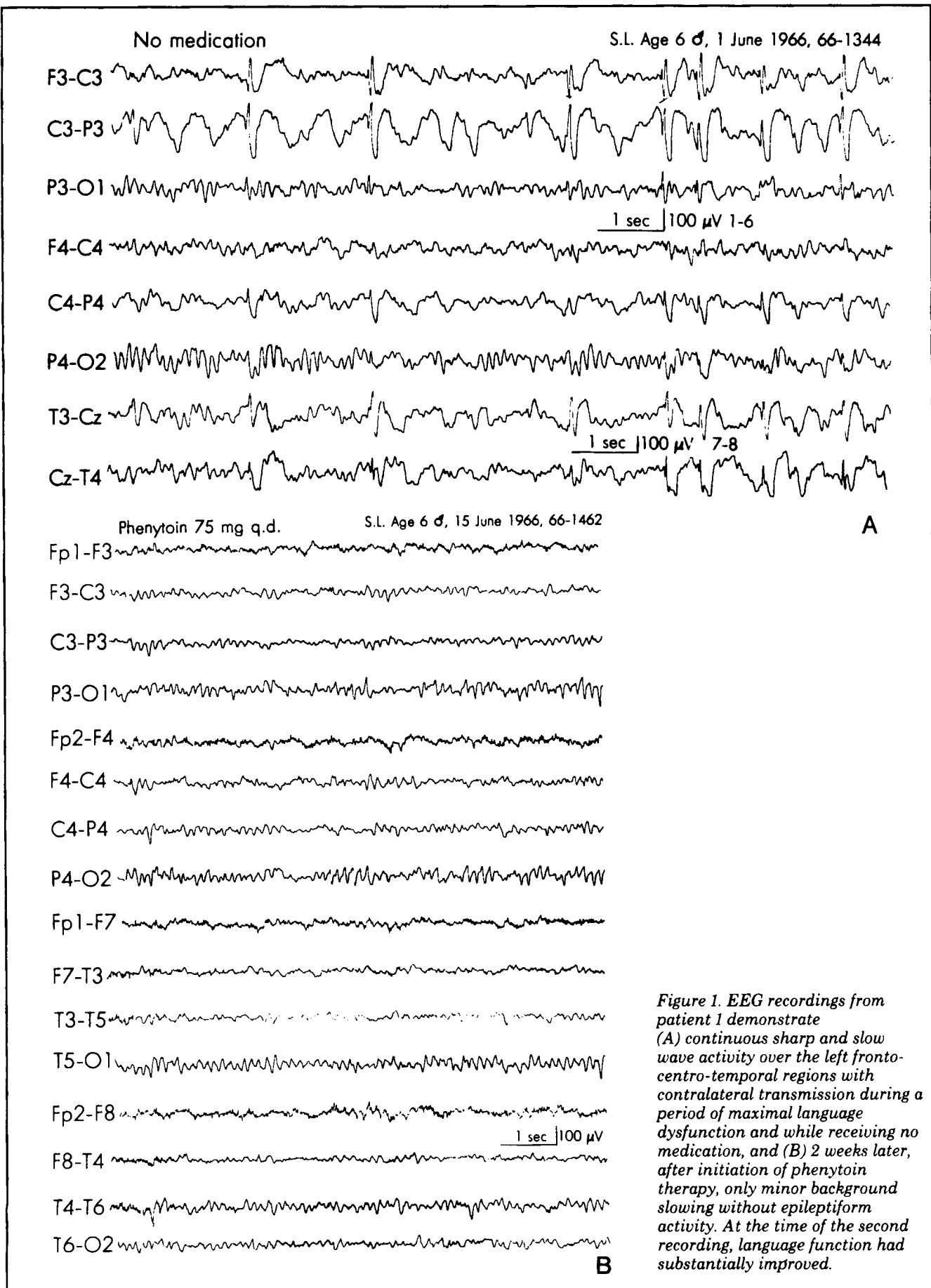
**Case reports. Patient 1.** S.L., a right-handed boy, was first reported by McKinney and McGreal.<sup>20</sup> He was born after a normal gestation and delivery. He walked and used his first words at 12 months. At 2 years, his family thought he had difficulty with hearing because of decreased comprehension of spoken commands. He underwent adenoidectomy and seemed to improve. At age 4 years, his hearing again seemed to deteriorate: he failed to answer questions and did not follow spoken instructions. At age 5, he had the vocabulary of a 3½- to 4-year-old. An EEG revealed diffuse left hemispheric epileptic abnormality. The patient was placed on phenytoin without clinical improvement.

Between the ages of 5 and 7 his language deficit fluctuated widely over periods of months, and included both receptive and expressive elements. During periods of maximal language

From the Montreal Neurological Hospital and Institute (Drs. Cole and Andermann, Mr. Taylor, and Drs. Olivier, Rasmussen, and Robitaille), McGill University, Montreal, Quebec, Canada; and the University of Chicago (Dr. Spire), Chicago, IL.

Presented in part at the thirty-seventh annual meeting of the American Academy of Neurology, Dallas, TX, April 1985.

Address correspondence and reprint requests to Dr. Andermann, Montreal Neurological Hospital and Institute, 3801 University Street, Montreal, Quebec, H3A 2B4, Canada.



*Figure 1. EEG recordings from patient 1 demonstrate (A) continuous sharp and slow wave activity over the left fronto-centro-temporal regions with contralateral transmission during a period of maximal language dysfunction and while receiving no medication, and (B) 2 weeks later, after initiation of phenytoin therapy, only minor background slowing without epileptiform activity. At the time of the second recording, language function had substantially improved.*

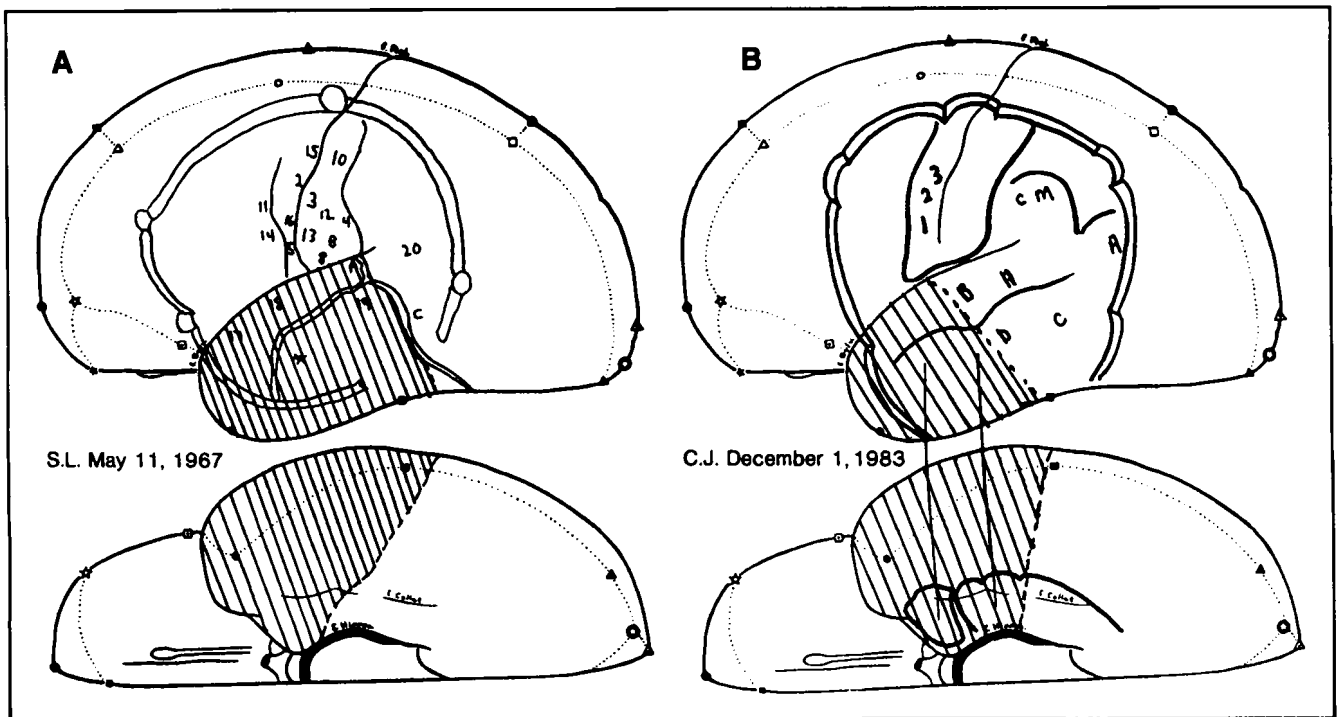


Figure 2. Brain maps from surgical records showing the limits of resections. Shaded areas were removed. The letters and numbers refer to sites of stimulation during corticography. (A) Patient 1: 5, 16, and 2 lie on the precentral gyrus, while 8, 13, and 3 lie on the postcentral gyrus. (B) Patient 2: 1, 2, and 3 lie on the precentral gyrus, B and A lie on the first temporal gyrus.

dysfunction, EEGs revealed almost continuous epileptiform disturbance over the left fronto-centro-temporal region. In contrast, when speech improved, the epileptic activity disappeared, leaving only minor slowing of background activity (figure 1). Unfortunately, this improvement was only transient.

At age 6½ years, speech and comprehension deteriorated markedly over 3 months. He had no seizures. On examination, he was alert but had no spontaneous speech. Although he turned his head when his name was called, he was unable to follow spoken commands. He seemed frustrated by his language difficulties, but he rapidly followed gestured commands.

Pneumoencephalography revealed slight generalized atrophy of the left cerebral hemisphere, most marked in the temporal lobe and in the adjacent regions of the parietal lobe. A left carotid arteriogram was normal.

An EEG showed an active focus of epileptogenic activity composed of slow sharp waves and 2-Hz spike and wave complexes from the left temporal, posterior temporal, and parietal regions with contralateral transmission. No independent right-sided epileptogenic abnormality was detected. Neuropsychological evaluation demonstrated language function at only the 2- to 3-year level. In contrast, nonverbal skills were in the low-average range with a performance IQ of 91.

At age 7, the patient underwent a left temporal lobectomy. Electrocuticography revealed high-amplitude rhythmic spikes from the parietal opercular and posterior temporal regions as well as from the hippocampus. Because of persistent epileptogenic activity after resection of the anterior 5 cm of the temporal lobe, the transverse gyrus of Heschl was removed (figure 2A). Post-resection corticography demonstrated persistent but reduced epileptic discharge from the posterior bank of the removal.

Neuropathologic examination of the surgical specimen showed normal gross appearance. Cytoarchitecture of the cor-

tex and underlying white matter showed only mild subpial gliosis. There was no evidence of inflammation, or loss of myelin. The hippocampus and ependyma were normal (figure 3).

Immediately after operation, speech improved rapidly. It was then possible to administer the verbal test of the WISC, which yielded a verbal IQ of 53. Performance IQ was measured at 101. Stories read to the patient were repeated in fragments. He reported twice as many digits presented to the left ear on dichotic testing as he had before operation, but reported no digits presented to the right ear. By the time of discharge, he was forming five- to seven-word sentences and had improved auditory comprehension.

Ten months later the patient was reevaluated. He was attending a special grade 1 class but required language therapy. His mother noted that he was speaking in sentences and seemed to chatter incessantly. He appeared happy and well behaved. On examination, he was slightly dysarthric. He was able to count to 30 with two errors, to identify colors, and to name objects. An EEG examination revealed active epileptogenic discharge from the left mid and posterior temporal regions.

Repeat neuropsychological testing showed that language comprehension had improved, but difficulty in discriminating between similar sounding words persisted. Although expressive language had also improved, words were occasionally unintelligible. His verbal IQ had increased to 65. He was able to remember twice as many story details as he had in the immediate postoperative period, and for the first time he was able to retain some of those details in delayed recall testing an hour later. There continued to be complete suppression of digits presented to the right ear on dichotic testing, while scores from the left ear continued to increase. Reading and writing skills were rudimentary; he misspelled his first name. Shortly thereafter, language and the EEG again deteriorated. Unfortunately, he has since been lost to follow-up.

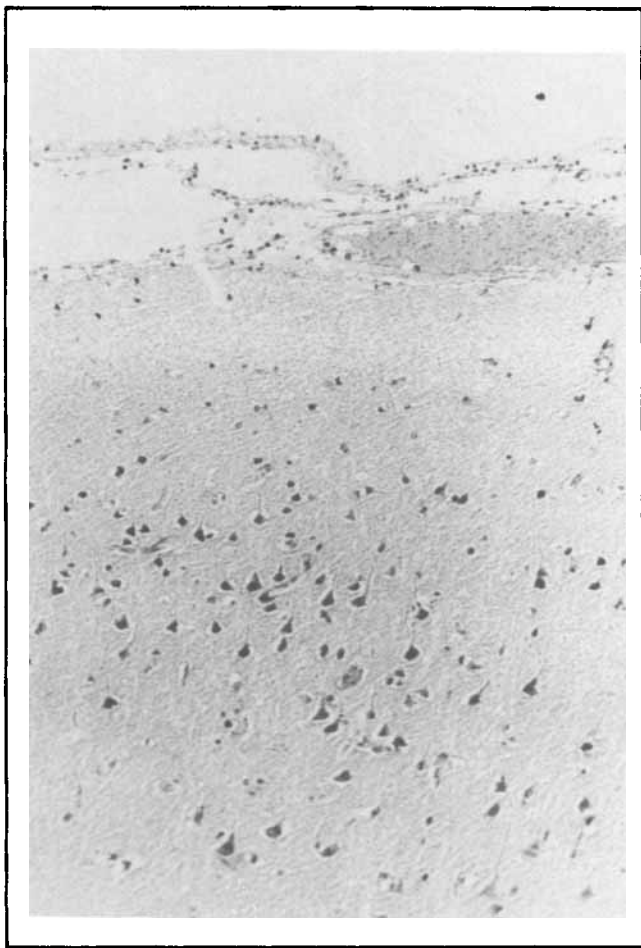

Figure 3. Temporal neocortex (patient 1) demonstrates normal architecture with mild subpial gliosis. (Hematoxylin and eosin, magnification  $\times 200$  before 30% reduction.)

**Patient 2.** C.J. is a 28-year-old right-handed woman. Gestation and delivery were uncomplicated. Developmental milestones were normal: she walked at 12 months and was using short sentences at 24 months.

When she was 4½ years old her parents noted occasional hesitation in her response to spoken commands. Over the next 15 months her language function regressed, with initial loss of verbal comprehension and eventual disappearance of all speech. Examination at that time revealed verbal auditory agnosia with mutism, preserved hearing, and mild right facial weakness. An EEG showed spike activity, but no further details are available.

At age 6 years, 18 months after the onset of language difficulty, she suffered her first convulsion, which began with jerking of the right arm and after an unknown interval became secondarily generalized. After the seizure she had a right Babinski response. An EEG demonstrated bursts of generalized multiple spike discharges followed by slow waves. CSF was normal, as was a left carotid arteriogram. Phenytoin was prescribed and the patient remained seizure-free for 1 year, with continued verbal auditory agnosia and mutism.

Between ages 7 and 12 years, she suffered eight generalized seizures and four episodes of generalized status epilepticus. Language deficits persisted, but she responded to environmental sounds, eg, the doorbell or the telephone. At age 12, she began having complex partial attacks. There was no aura. The spells were characterized by staring, chewing, and automatic

movements of the right hand, as well as occasional cursive episodes.

By age 13, behavioral changes were noted. She became intermittently withdrawn and belligerent. Neuropsychological testing showed a performance IQ of 96, but evaluators commented on strikingly poor social adjustment. Verbal language deficits were severe, but she used sign language and finger spelling for communication. Over the next 10 years she continued to suffer frequent complex partial seizures, infrequent generalized convulsions, and progressive behavioral deterioration.

There was no family history of seizures, language disorder, or psychiatric disease. At age 28, she was a mute woman who sometimes used sign language or finger spelling for communication. She did not respond to oral commands, but was able to read simple sentences and follow written instructions. She was able to respond correctly to 38 of the first 40 items of the Token Test of Language Comprehension when these simple directions were presented visually. Her score on the Peabody Picture Vocabulary test was at the 2-year, 6-month level. Prolonged maintenance of bizarre postures with waxy flexibility was frequently noted. There were no focal neurologic deficits.

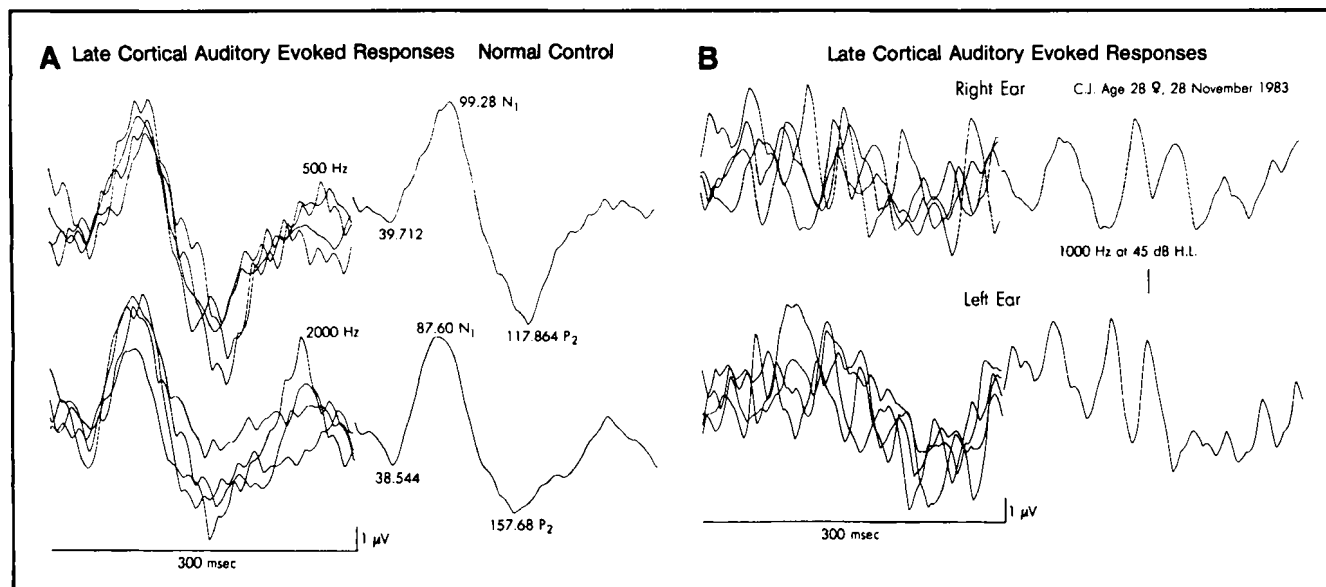
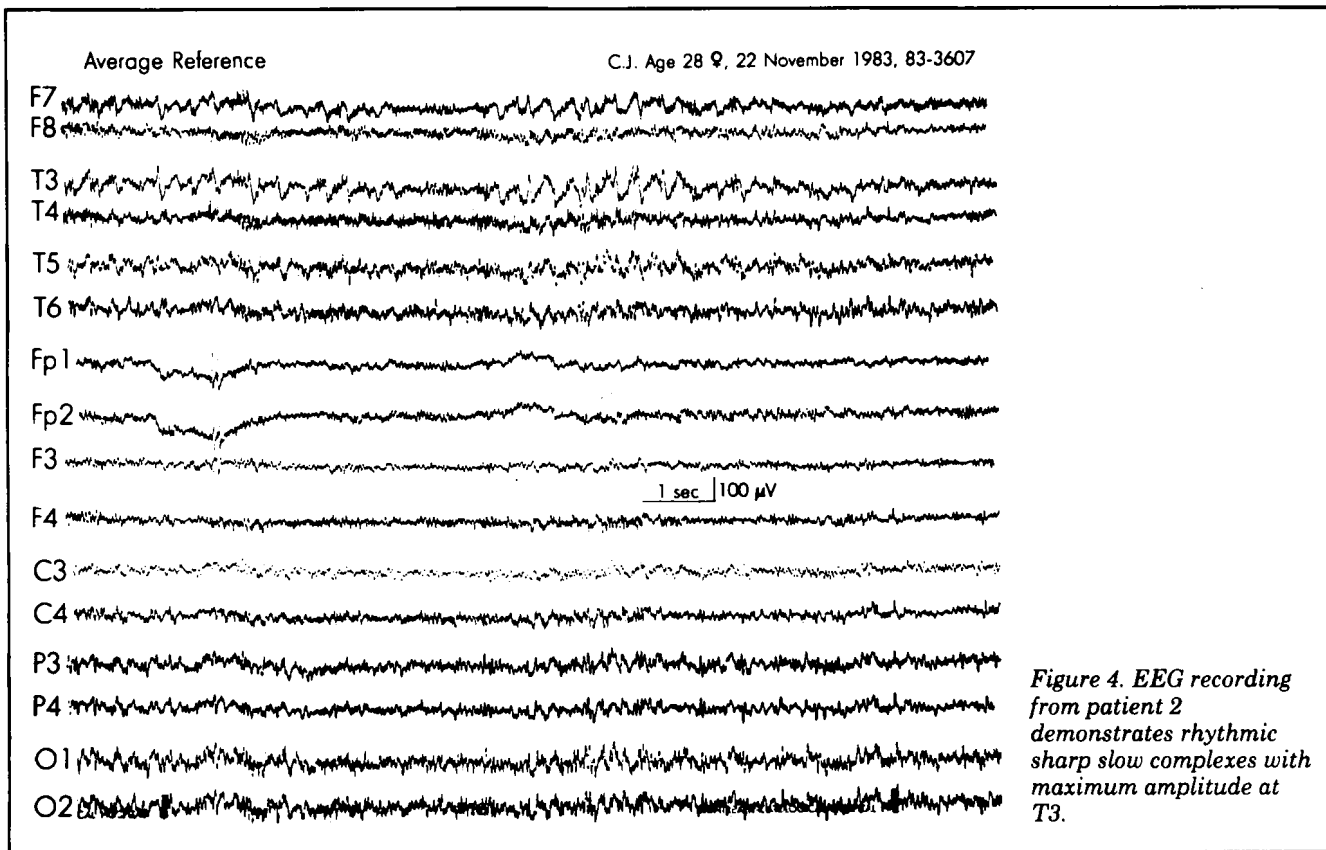
Multiple EEG recordings from scalp and sphenoidal electrodes revealed striking rhythmic slow and slow sharp activity over the left temporal region (figure 4). In addition, there were similar less active independent contralateral epileptic discharges. An electrographic seizure without clinical accompaniment consisted of rhythmic 2½- to 3-cps sharp and slow wave complexes over the left temporal region, with phase reversals at T3 and on occasion at SP1.

Audiograms were normal, demonstrating speech detection at 15 dB in each ear. Brainstem auditory evoked responses (BAERs) were normal on two occasions. Attempts were made to measure cortical evoked responses (CERs). Pure-tone stimuli at varying frequencies were presented with 0.9-msec rise-fall time and 250-msec duration. Stimulus levels were 50 and 70 dB HL. Recording was from electrode position FPz, referred to the medial surface of the test ear. On four different occasions, CERs were absent in spite of normal BAERs. Specifically, N1 (125 msec) and P2 (250 msec) could not be demonstrated (figure 5).

Skull x-rays were normal. Head CTs with and without contrast infusion demonstrated slight enlargement of the left temporal horn. PET was used to study glucose utilization and oxygen uptake. Twelve partial complex attacks were observed during the 10 days prior to the PET study, but no seizures were recorded by telemetered EEG monitoring during the scans obtained after administration of  $^{18}\text{F}$ FDG and  $^{15}\text{O}_2$ . Glucose utilization was reduced by 50% in the right temporal region when compared with the left. This was associated with a 40% decrease in regional cerebral blood flow in the same region, as compared with the contralateral temporal lobe.

Because of uncontrollable complex partial seizures, resection of the anterior 5.5 cm of the left temporal lobe was carried out under general anesthesia (figure 2B). Electrocorticography showed spiking activity posteriorly over the temporal lobe. Chronic herniation of the uncus at the incisura was reported. The amygdala and the parahippocampal gyrus were abnormally firm. Post-resection corticography demonstrated reduced but persistent spiking from the posterior bank of the removal.

Neuropathologic examination of the resected specimen showed slight widening of the temporal sulci. Gyri were firm and rubbery. White and gray matter distinction was well preserved. Microscopic examination showed normal cytoarchitecture with preservation of vertical and horizontal cortical lamination. There was mild subpial gliosis with mini-



mal white matter gliosis. Occasional fibrous astrocytes were seen throughout the cortical gray matter. There was no evidence of chronic infection or dysgenesis (figure 6).

One year after operation, the parents reported qualitative improvement in communication ability. Seizure frequency was estimated at 10% of the preoperative level. Psychotic features had largely disappeared. She was noted to enjoy music and sewing, and was able to manage her own finances. Neu-

rologic examination showed continued VAAM but striking reduction in schizophreniform behavior. Neuropsychological testing confirmed a continued severe disturbance of speech skills with preservation of reading, writing, and signing ability, in contrast to near normal scores on a variety of visuo-spatial tests.

EEG showed infrequent epileptiform sharp waves with phase reversal at T3. The rhythmic activity seen previously

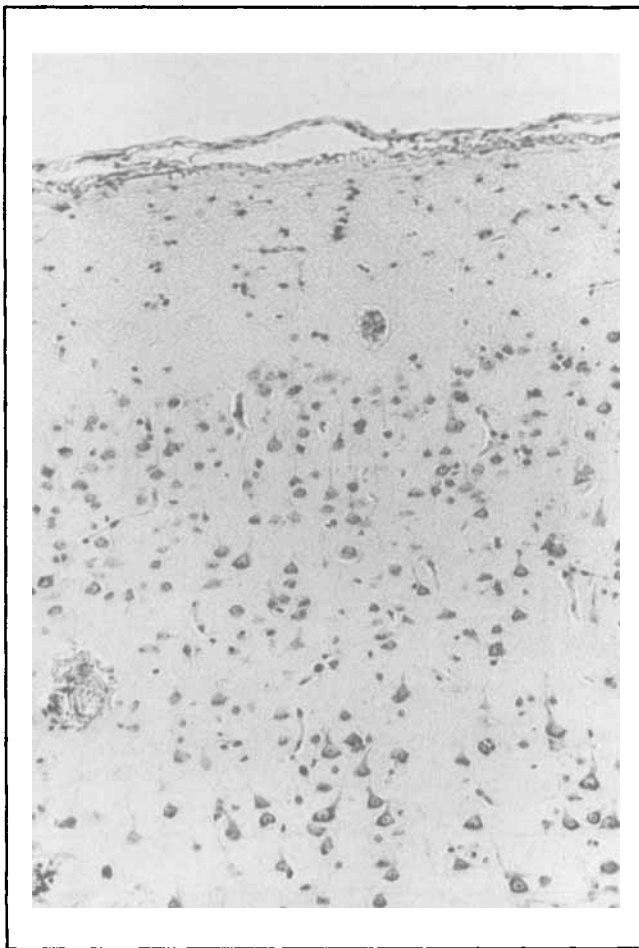


Figure 6. Temporal neocortex (patient 2) shows normal architecture with well-preserved lamination and no evidence of inflammation. (Klüver-Barrera stain, magnification  $\times 150$  before 31% reduction.)

was no longer apparent, and contralateral discharges were not seen. BAERs were normal, but once again CERs could not be elicited.

**Discussion.** These two patients represent opposite ends of the clinical spectrum of the syndrome of acquired epileptic verbal auditory agnosia and mutism. Both commenced in the usual way with gradual loss of receptive and then expressive language function and emergence of EEG abnormalities. The first patient continued to evolve in the typical fashion. He never developed seizures. There was a strong correlation between the severity of the language disorder and the presence of epileptogenic EEG abnormalities. He was treated surgically at a time when the natural history of this syndrome was less clear, with the hope of improving language by removing tissue producing continuous electrographic abnormalities. The second patient evolved in an unusual manner to develop severe independent bitemporal epileptic abnormalities, uncontrollable complex partial seizures, and later a chronic schizophreniform disorder. She was operated in the hope that reducing the seizure tendency would enable her to live more independently. In neither case could an underlying

cause for the disease be identified.

The PET data obtained from the second patient are difficult to interpret. She had bilateral independent epileptic abnormalities, but both preoperative studies and the postoperative course suggest that the predominant interictal abnormality and the seizures originated on the left side. The left temporal region displayed more epileptic activity as monitored with scalp and sphenoidal EEG recording throughout the period when PET studies were performed, but no seizures occurred during the glucose or oxygen scans. The PET data showing relative right temporal hypometabolism must therefore be interpreted as supporting the presence of bitemporal dysfunction.

Neuropsychological assessment of both these patients was limited by their language comprehension difficulties and their lack of expressive speech. In spite of these limitations, it was possible to show that both patients had relative preservation of visuospatial skills in contrast to their severe language impairments. In the first patient, continued suppression of digits presented to the right ear in the dichotic condition pointed to ongoing disturbance of function in the primary auditory cortex of the left hemisphere. In the second patient, simple span tests using verbal and visuospatial sequences demonstrated limited function of the left hemisphere in contrast to almost normal function of the right hemisphere.

Normal audiograms with preserved brainstem auditory evoked responses confirmed the integrity of subthalamic auditory pathways. The inability to demonstrate long-latency cortical evoked responses, however, supports the hypothesis that this patient suffered from bilateral posterior temporal cortical dysfunction. Woods et al<sup>35</sup> have reviewed the localization of N1 and P2 generators using animal models, particularly the cat. They also studied a patient with bilateral posterior temporal infarcts and cortical deafness, and concluded that these waveforms are generated by the cortex in area 39, the angular gyrus, but not precisely in the primary auditory cortex (areas 41 and 42). In addition, experimental evidence suggests that these waveforms are generated bilaterally, and thus a unilateral lesion may result in reduced amplitude but not in disappearance of these potentials, as seen in our case.

Review of 95 cases reported in 25 publications, as well as our 2 cases, allowed localization or lateralization of epileptogenic abnormalities in 74 instances. In 88%, discharges were either bitemporal, generalized, or multifocal (including those cases with shifting lateralization). In only 13 cases (12%) were strictly unilateral discharges reported: 10 patients had left temporal or central discharges and 3 had right-sided discharges. In both bilateral and unilateral cases, there was a strong predominance of temporal localization. In 72% of the 39 cases for which information is available, severity of the language dysfunction and the EEG abnormality were positively correlated. Our first case is an example of this phenomenon. One must be cautious in interpreting such retrospective data, since further recording might have shown contralateral, generalized, or shifting abnormalities. Predominance of bilateral epileptogenic

activity in the great majority suggests that this is important in the development of the syndrome.

The morphology of the EEG abnormality in this condition is distinctive, and is reminiscent of the EEG findings in the benign rolandic and occipital epilepsies of childhood<sup>36,37</sup>; however, the localization is mainly temporal in this condition. A similar conclusion has been reached independently by Dulac et al.<sup>38</sup> Spikes tend to be of high amplitude with shifting lateralization, background is well preserved, and epileptic activity is often sensitive to anticonvulsant therapy. In addition, Rodriguez and Niedermeyer,<sup>25</sup> in a report of four cases of acquired epileptic aphasia studied with sleep recording, demonstrated a dramatic increase in epileptic abnormalities during sleep, similar to that seen in benign rolandic epilepsy. The presence of slow spike and wave in many of these cases may be reminiscent of secondary generalized epilepsy; however, the degree of focalization and shifting lateralization is greater than expected in that disorder.

Epileptic seizures in the present syndrome are usually benign. Thirty percent of patients have no seizures at all,<sup>2</sup> and in the remainder, attacks are brief, easily controlled, and generally do not progress to status epilepticus. Patients seldom manifest the frequent minor attacks so often seen in the various forms of secondary generalized corticoreticular epilepsy that lead to mental deterioration. Only exceptionally does the syndrome proceed to malignant epilepsy, as in our second case.

The neuropathologic basis of this disorder has been much debated and an encephalitic etiology frequently postulated. The clinical course of the Landau-Kleffner syndrome is quite different from that of children with chronic encephalitis of the Rasmussen type.<sup>39</sup> In that condition, *epilepsia partialis continua* is practically always present, and dysphasia may also occur. Patients always progress to develop severe neurologic deficit before the disorder becomes arrested. Mild forms of the disorder may be postulated but have not so far been documented.

A cortical biopsy was performed by Lou et al<sup>15,16</sup> in a patient whose condition resembled the Landau-Kleffner syndrome, but their case was atypical insofar as the CSF protein was elevated, brain scan showed focal temporal abnormality, and the patient developed a bulbar paralysis. The relevance of the biopsy findings suggesting chronic encephalitis in their case is therefore uncertain. In neither of our cases was there pathologic evidence of chronic encephalitis<sup>40</sup> although we looked specifically and carefully for this. In both our cases, mild gliosis was seen, and in the second case there was evidence of hippocampal sclerosis. No dysgenetic lesion or abnormality of cortical architecture could be discovered. Pathologic analysis of biopsy specimens can be biased by sampling error, especially in cases of focal epilepsy where the causative lesion may be remote from the most active focus. In the absence of autopsy data, however, our cases emphasize that chronic encephalitis does not appear to play a role in this disease.

Long-term prognosis in this disorder is difficult to predict due to a relative lack of studies reporting adequate long-term follow up. Bishop,<sup>41</sup> in a review of 45

cases from the literature in which there was follow-up to at least age 12 years, has suggested that prognosis correlates to a certain degree with the age at onset, with those patients affected early having a worse prognosis than those affected late. This conclusion is supported by the data of Toso et al<sup>30</sup> and Dulac et al.<sup>38</sup> In cases of structural brain disease, it has been shown that before age 5 or 6 years, there is considerable plasticity of language representation, and significant injury to the dominant hemisphere is capable of forcing language function into the contralateral hemisphere.<sup>42</sup> In early-onset cases of the present disorder, one must hypothesize that either the dominant hemisphere is not compromised sufficiently to force this shift, or that nonstructural or subacute disease of the dominant hemisphere does not result in the same plastic changes seen with structural or acute disease, or that dysfunction must be bilateral. Better prognosis in cases with later onset suggests that language dysfunction in this syndrome may be related to disordered auditory processing of verbal information, and not to frank disruption of areas involved in higher order language processing.<sup>41</sup> Because of extensive representation of the auditory cortex in both hemispheres, bilateral dysfunction must again be postulated. Cortical auditory evoked response data from our second case support this contention.

## References

1. Landau WM, Kleffner FR. Syndrome of acquired aphasia with convulsive disorder in children. *Neurology* 1957;7:523-530.
2. Beaumanoir A. The Landau-Kleffner syndrome. In: Roger J, Dravet C, Bureau M, Dreifuss FE, Wolf P, eds. *Epileptic syndromes in infancy, childhood and adolescence*. London: John Libbey, 1985:181-191.
3. Beaussart M, Faou R. Evolution of epilepsy with rolandic paroxysmal foci: a study of 324 cases. *Epilepsia* 1978;19:337-342.
4. Cooper J, Ferry P. Acquired auditory verbal agnosia and seizures in childhood. *J Speech Hear Disord* 1978;43:176-184.
5. Deonna T, Beaumanoir A, Gaillard F, et al. Acquired aphasia in childhood with seizure disorder: a heterogeneous syndrome. *Neuropaediatrics* 1977;8:263-273.
6. Deonna T, Fletcher P, Voumard C. Temporary regression during language acquisition: a linguistic analysis of a 2½-year-old child with epileptic aphasia. *Dev Med Child Neurol* 1982;24:156-163.
7. Deuel RK, Lenn NJ. Treatment of acquired epileptic aphasia. *J Pediatr* 1977;90:959-961.
8. Dugas M, Grenet P, Masson M, et al. Aphasie de l'enfant avec épilepsie. Évolution régressive sous traitement antiépileptique. *Rev Neurol (Paris)* 1976;132:489-493.
9. Foerster C. Aphasia and seizure disorders in childhood. In: Penry JK, ed. *Epilepsy: the Eighth International Symposium*. New York: Raven Press, 1977:305-306.
10. Gascon G, Victor D, Lombroso CT, et al. Language disorder, convulsive disorder, and electroencephalographic abnormalities. *Arch Neurol* 1973;28:156-162.
11. Giovanardi Rossi P, Pazzaglia P, Frank G. Afasia acquisita con anomalie convulsive nell'età evolutiva: studio clinico, neuropsicologico ed elettroencefalografico di un caso. *Riv Neurol* 1976;46:130-162.
12. Holmes GL, McKeever M, Saunders Z. Epileptiform activity in aphasia of childhood: an epiphenomenon? *Epilepsia* 1981;22:631-639.
13. Koepf P, Lagenstein I. Acquired epileptic aphasia. *J Pediatr* 1978;92:164.
14. Lanzi G, Bojardi A. Illustrazione di un caso di afasia acquisita. *Neuropsychiatria Infantile* 1970;206:135-156.
15. Lou HC, Brandt S, Bruhn P. Progressive aphasia and epilepsy



- with a self-limited course. In: Penry JK, ed. *Epilepsy: the Eighth International Symposium*, New York: Raven Press, 1977:295-303.
16. Lou HC, Brandt S, Bruhn P. Aphasia and epilepsy in childhood. *Acta Neurol Scand* 1977;56:46-54.
  17. Lugaresi E. L'afasia nelle regressioni mentali infantili. *Riv Sper Freniat* 1958;82:935-948.
  18. Maccario M, Hefferen SJ, Keblusek SJ, Lipinski KA. Developmental dysphasia and electroencephalographic abnormalities. *Dev Med Child Neurol* 1982;24:141-155.
  19. Mantovani JF, Landau WM. Acquired aphasia with convulsive disorder: course and prognosis. *Neurology* 1980;30:524-529.
  20. McKinney W, McGreal DA. An aphasic syndrome in children. *Can Med Assoc J* 1974;110:637-639.
  21. Perniola T, Pennetta R. Afasia acquisita in soggetto con crisi convulsive ed anomalie elettroencefalografiche bitemporali. *Riv Neurol* 1975;45:79-86.
  22. Petersen U, Koepf P, Solmsen M, Villiez TH. Aphasia im Kindesalter mit EEG-Veränderungen. *Neuropaediatric* 1978;9:84-96.
  23. Rapin I, Mattis S, Rowan AJ, et al. Verbal auditory agnosia in children. *Dev Med Child Neurol* 1977;19:192-207.
  24. Rose FC. Receptive aphasia in childhood. Abstract. *J Neurol Neurosurg Psychiatry* 1969;32:67.
  25. Rodriguez I, Niedermeyer E. The aphasia-epilepsy syndrome in children: electroencephalographic aspects. *Clin Electroencephalogr* 1982;13:23-35.
  26. Rousseaux M, Devos P. Surdit , mutisme et troubles du comportement par l sions c r brales bitemporales. *Cortex* 1983;19:557-568.
  27. Sato S, Dreifuss FE. Electroencephalographic findings in a patient with developmental expressive aphasia. *Neurology* 1973;23:181-185.
  28. Shoumaker RD, Bennett DR, Bray PF, Curless RG. Clinical and EEG manifestations of an unusual aphasic syndrome in children. *Neurology* 1974;24:10-16.
  29. Stein LK, Curry FKW. Childhood auditory agnosia. *J Speech Hear Disord* 1968;34:361-370.
  30. Toso V, Maschini M, Gagnin G, et al. Aphasia acquise de l'enfant avec  pilepsie. *Rev Neurol (Paris)* 1981;137:425-434.
  31. Van Harskamp F, Van Dongen HR, Loonen MCB. Acquired aphasia with convulsive disorder in children: case study with seven year follow-up. *Brain Lang* 1978;6:141-148.
  32. Watters GV. The syndrome of acquired aphasia and convulsive disorder in children. *Can Med Assoc J* 1974;110:611-612.
  33. Worster-Drought C. An unusual form of acquired aphasia in children. *Dev Med Child Neurol* 1971;13:563-571.
  34. Alajouanine TH, L'Hermitte F. Acquired aphasia in children. *Brain* 1965;88:653-662.
  35. Woods DL, Knight RT, Neville HJ. Bitemporal lesions dissociate auditory evoked potentials and perception. *Electroencephalogr Clin Neurophysiol* 1984;57:208-220.
  36. Louiseau P, Beaussart M. The seizures of benign childhood epilepsy with rolandic paroxysmal discharges. *Epilepsia* 1973;14:381-389.
  37. Lombroso CT. Sylvian seizures and midtemporal spike foci in children. *Arch Neurol* 1967;17:52-59.
  38. Dulac O, Billard C, Arthuis M. Aspects  lectro-cliniques et  volutifs de l' pilepsie dans le syndrome aphasia- pilepsie. *Arch Fr P diatr* 1983;40:299-308.
  39. Rasmussen T, McCann W. Clinical studies of patients with focal epilepsy due to "chronic encephalitis". *Trans Am Neurol Assoc* 1968;93:89-94.
  40. Aguilar MJ, Rasmussen T. Role of encephalitis in pathogenesis of epilepsy. *Arch Neurol* 1960;2:663-676.
  41. Bishop DVM. Age at onset and outcome in 'acquired aphasia with convulsive disorder' (Landau-Kleffner syndrome). *Dev Med Child Neurol* 1985;27:705-712.
  42. Rasmussen T, Milner B. The role of early left-brain injury in determining lateralization of cerebral speech functions. *Ann NY Acad Sci* 1977;299:355-369.



## Genetic factors in myasthenia gravis: A family study

L. Kerzin-Storarr, MS; R.A. Metcalfe, MRCP; P.A. Dyer, PhD; G. Kowalska, BSc; I. Ferguson, MD, MRCP;  
and R. Harris, MD, FRCP, FRCPATH

**Article abstract**—We studied forty-four patients with myasthenia gravis (MG) and their families. Thirty percent of patients had a confirmed family history of autoimmune disease; in one case this was MG. In all the families with autoimmune disease, the affected relatives were related to the patients through the maternal line. HLA-B8 and DR3 were increased in patients due to the high incidence of these antigens in female, nonthymoma patients with onset before 40 years. HLA-B5 was increased in patients with older onset. The haplotype A1-B8-DR3 was not found to be increased given the presence of B8 or DR3.

NEUROLOGY 1988;38:38-42

The mechanism that gives rise to the production of autoantibodies directed against acetylcholine receptors in myasthenia gravis (MG) is unknown and may vary between patients. MG appears to be a heterogeneous condition; a number of studies have attempted to subdivide the disease based on clinical and laboratory data

(sex, age at onset, thymus histology, severity of disease, and level of anti-acetylcholine receptor antibodies).<sup>1,2</sup> The contribution of genetic factors to the etiology of MG has also been investigated. Although MG itself rarely recurs within families,<sup>3,4</sup> patients as well as their relatives often suffer from other autoimmune condi-

From the Department of Medical Genetics (Ms. Kerzin-Storarr, Dr. Dyer, Ms. Kowalska, and Prof. Harris), St. Mary's Hospital, and the Department of Neurology (Drs. Metcalfe and Ferguson), Manchester Royal Infirmary, Manchester, England.

Received December 1, 1986. Accepted for publication in final form April 6, 1987.

Address correspondence and reprint requests to Ms. Kerzin-Storarr, Regional Genetic Service at St. Mary's Hospital, Central Manchester Health Authority, Whitworth Park, Manchester M13 0JH, England.

**The Landau–Kleffner syndrome of acquired epileptic aphasia: Unusual clinical outcome, surgical experience, and absence of encephalitis**

A. J. Cole, F. Andermann, L. Taylor, et al.

*Neurology* 1988;38;31

DOI 10.1212/WNL.38.1.31

**This information is current as of January 1, 1988**

<b>Updated Information &amp; Services</b>	including high resolution figures, can be found at: <a href="http://www.neurology.org/content/38/1/31.full.html">http://www.neurology.org/content/38/1/31.full.html</a>
<b>Citations</b>	This article has been cited by 6 HighWire-hosted articles: <a href="http://www.neurology.org/content/38/1/31.full.html#otherarticles">http://www.neurology.org/content/38/1/31.full.html#otherarticles</a>
<b>Permissions &amp; Licensing</b>	Information about reproducing this article in parts (figures, tables) or in its entirety can be found online at: <a href="http://www.neurology.org/misc/about.xhtml#permissions">http://www.neurology.org/misc/about.xhtml#permissions</a>
<b>Reprints</b>	Information about ordering reprints can be found online: <a href="http://www.neurology.org/misc/addir.xhtml#reprintsus">http://www.neurology.org/misc/addir.xhtml#reprintsus</a>